

# A systematic review and quality assessment of case reports of adverse events for borage (*Borago officinalis*), coltsfoot (*Tussilago farfara*) and comfrey (*Symphytum officinale*)



Catharine Avila<sup>a</sup>, Ian Breakspear<sup>b</sup>, Jason Hawrelak<sup>c,d</sup>, Ses Salmond<sup>e</sup>, Sue Evans<sup>c,\*</sup>

<sup>a</sup> Southern Cross University, Australia

<sup>b</sup> Endeavour College of Natural Health, Australia

<sup>c</sup> University of Tasmania, Australia

<sup>d</sup> Australian Research Centre for Complementary and Integrative Medicine, University of Technology Sydney, Sydney, Australia

<sup>e</sup> Liverpool Women's Health Centre, Australia

## ARTICLE INFO

### Keywords:

Pyrrrolizidine alkaloids  
Comfrey  
Coltsfoot  
Borage  
Adverse events  
Systematic review

## ABSTRACT

*Symphytum officinale* (comfrey), *Tussilago farfara* (coltsfoot) and *Borago officinalis* (borage) have long histories of therapeutic use, but their safety has been questioned due to the presence of unsaturated pyrrolizidine alkaloids (PAs). The evidence base underlying these concerns relies in part on case reports. This systematic review assesses these case reports for their reliability to inform this debate.

**Method:** Study selection was restricted to case reports describing possible pyrrolizidine alkaloid related harm and ingestion of comfrey, coltsfoot or borage. An extensive search of academic databases was conducted. Papers meeting the criteria were critically appraised.

**Results:** The search resulted in 11 appropriate case reports, none of which involved borage. Nine reports were assessed for causality and indicated some degree of association between the material ingested and the adverse event. Lack of unequivocal identification of the species ingested compromised attribution and was a significant source of uncertainty. Three levels of identity confusions were found; misidentification or substitution at the level of the whole herb; omission of appropriate botanical identification and attribution of a specific PA to either comfrey or coltsfoot when it is a constituent found in other plants of established toxicity.

**Conclusion:** These cases are an unreliable body of evidence on which to draw conclusions about the safety of the oral consumption of *Symphytum officinale* and *Tussilago farfara*. Toxicological studies based on oral ingestion of phytochemically-complex preparations of these herbs may be the most accurate methodology for assessing clinical risk.

## 1. Introduction

This review focuses on three medicinal plants *Symphytum officinale* (comfrey), *Tussilago farfara* (coltsfoot) and *Borago officinalis* (borage) which have long histories of therapeutic use in Western herbal medicine and like some 600 other plant species, contain pyrrolizidine alkaloids (PAs) [1]. These compounds have been responsible for outbreaks of acute poisoning in a number of communities when food, including bush teas, were contaminated by varieties of *Heliotropium*, *Crotalaria* and *Senecio* which contain 1,2 unsaturated PAs [2–4]. Unsaturated PAs display no toxicity in their native form. Metabolic activation is a necessary step to exert toxicities and involves three main pathways – N-oxidation to produce pyrrolizidine alkaloid N-oxides (PANOs);

hydrolysis to create necines and necic acids; and oxidation to form either pyrrolic esters or dehydropyrrolizidine alkaloids (DHPAs) [5,6]. As biotransformation of PAs occurs mostly in the liver, this organ is the most affected by the toxic PA metabolites and in humans the characteristic pathology associated with PA toxicity is hepatic veno-occlusive disease (HVOD), although the lungs may also be affected leading to pulmonary arterial hypertension [3,7]. Metabolites of at least five unsaturated PAs (retrorsine, riddelliine, monocrotaline, lasiocarpine and heliotrine) may form DNA adducts in the liver and have been associated with hepatic carcinoma in rodent studies, but these have not to our knowledge been identified in humans [2,6].

Pyrrolizidine alkaloids are also found in common foodstuffs. It is the potential long-term health risks of low dose chronic exposure to this

\* Corresponding author.

E-mail address: [sue.evans@utas.edu.au](mailto:sue.evans@utas.edu.au) (S. Evans).

<https://doi.org/10.1016/j.fitote.2020.104519>

Received 25 October 2019; Received in revised form 19 February 2020; Accepted 19 February 2020

Available online 24 February 2020

0367-326X/ © 2020 The Author(s). Published by Elsevier B.V. This is an open access article under the CC BY-NC-ND license (<http://creativecommons.org/licenses/by-nc-nd/4.0/>).

class of compounds from foods that is the cause of recent concern. The European Medicines Agency (EMA) has identified milk, eggs, honey, pollen products, grain and meat, and herbal products, including borage and comfrey consumed in salads, as sources of PAs [8]. Understanding this risk and estimating safe intakes is no simple task and a considerable literature evidences the multiple variables involved. These variables include differences in the toxicity of a given PA and associated metabolites, differences in constituent PAs both within and between species, differences in PA bioavailability from different preparations of the same herb and individual responses in consumers which may relate to age, gender and nutritional status [2,6,9,10]. Time of harvesting of plants is also a factor as concentrations fluctuate during the growth cycle and within plant part [11].

The assessments of risks to humans is largely based on mechanistic toxicology and is heavily reliant on animal studies [9]. Whilst mechanistic data clearly demonstrates the potential for a causal relationship between unsaturated PA metabolites and tissue damage [6], it can also be expected that the degree of damage will vary depending upon the unique structural characteristics of different unsaturated PAs [12], and risk assessments involving Margins of Exposure (MOE) calculations tend to base the calculations on only one structure, creating the potential for substantial uncertainty [9]. However numerous researchers refer to the available evidence from human case studies when reporting or reviewing research on PAs, including case reports involving the possible ingestion of comfrey or coltsfoot or borage (recent examples include [13–15]). The research discussed here considers the validity of the evidence derived only from case studies of these three herbs when orally ingested. We do not review the mechanistic evidence or recommendations for levels of consumption from all sources of PAs, such as those discussed by the European Food Safety Authority (EFSA) 2017 [9].

The EMA states that ‘according to the published literature, it is possible that the average dietary daily intake might already be more than the amounts of toxic, unsaturated PAs which are seen to be safe’ [16]. For these reasons PAs are the focus of ongoing international concern, with regulatory authorities now attempting to determine safe levels of intake. Low et al., point out that methods used for risk assessment are highly conservative in that they utilise ‘worst case scenarios’ in relation to the assumptions made for lifetime daily exposure of these foodstuffs [17]. However other authors suggest that the low levels found in these common foodstuffs may be unrecognised causes of a range of serious health concerns [9]. Chen and colleagues (2019) have questioned the accuracy of the usual Margins of Exposure (MOE) risk assessment method for determining risk of PAs in regards to herbal medicines, as MOEs are typically based on the assumption of life-long everyday use [10]. In their research, Chen et al. evaluated the potential impact of regular short-term exposure of PA-containing plants prepared as infusions and found a much-reduced level of risk. These researchers believe such an approach is more representative of real-world use and more accurately answer questions about the potential toxicity of typical use of PA-containing herbal medicines, such as coltsfoot, comfrey, and borage [10].

Comfrey, coltsfoot and borage are part of the armamentarium of the Western herbalists. From the 17th century, Gerard [18] documents their therapeutic action - coltsfoot for coughs, comfrey for internal and external wounds, and borage which ‘always brings courage’. These actions are still promoted 350 years later, albeit using terms which reflect a more specific understanding of pathology, with the *British Herbal Pharmacopeia* [19] recommending coltsfoot for bronchitis, laryngitis and asthma and comfrey for gastric and duodenal ulcers and colitis, as well as skin ulcers and wounds. At a similar time-period, 20th century authors from Fernie to Weiss refer to the long-established use of borage as a mood enhancer [20,66]. Interest in the phytopharmacology of comfrey dates back at least to 1912 when Macalister reported the presence of allantoin and its promoting effect on cell proliferation [21]. Recent research confirms, that apart from pyrrolizidine alkaloids,

comfrey's constituents include allantoin, phenolics, glycopeptides and polysaccharides, while both *in vitro* and animal investigations demonstrate antioxidant, anti-inflammatory and anti-microbial activity likely to contribute to comfrey's efficacy [22–24].

Due to their PA content, these plants are increasingly seen as a public health issue, and regulatory recommendations and restrictions on their use have been put in place in many jurisdictions where they are used [8]. In Australia comfrey, coltsfoot and borage cannot be legally prescribed for internal use, in Germany and the Netherlands short-term use of a prescribed dose is recommended (up to six weeks use at dose levels of 1 µg/day), while the European Medicines Agency recommends two weeks as the maximum duration of use when insufficient safety data is established regarding a herbal medicine [16,17,25,26]. However, some herbalists are concerned about the extrapolation from individual constituents tested *in vitro* and in animal models to clinical experience based on the use of whole plants [27].

While human data regarding long-term exposure is difficult to gather, reports of suspected involvement of comfrey and coltsfoot in this issue have been published since the mid-1980s. Two forms of comfrey, *Symphytum officinale* and *S. x uplandicum*, have been implicated in this controversy. *S. officinale* has been a valued medicinal plant for many generations, and questions about its safety were not raised until the 1980s. *S. x uplandicum* is a more recently introduced plant associated with a range of benefits in agriculture and food. Coltsfoot and borage have less popular and unique applications than comfrey and have been less consistently researched. Borage leaves contain unsaturated PAs, raising concerns in some parts of Europe where these are used as a salad vegetable [16]. However, research also indicates that its ingestion may be useful in gastric cancer prevention [28,29–30].

Since no randomised controlled trials (RCTs) investigating the internal use of these three herbal medicines have been published to our knowledge, assessment of their safety in humans relies, in part, on observational methodologies. In the absence of rigorous cohort studies, the best available evidence may be provided by case reports describing adverse events in individuals ingesting comfrey, borage or coltsfoot published in the peer-reviewed literature.

Whilst it is understood that randomised controlled trials are the appropriate methodology for determining efficacy and formal dose-response toxicology studies are required for determining safety, information gleaned from case studies is often used to inform safety-related decisions and policy. In the case of PAs, case reports of toxicity or serious adverse events associated with PAs should best serve as signals to conduct formal toxicology studies. Despite the limitations of case reports, which make them unreliable to make safety determinations especially of long term harm and potential carcinogenicity, they do provide data on oral toxicity concerns which may be more clinically relevant than the extrapolations made from *in vitro* and animal experiments. The aim of this systematic review is to find all relevant case reports and assess their reliability to inform the debate about the potential toxicity of the oral consumption of comfrey, coltsfoot and borage.

## 2. Identification of studies

In early December 2017, two of the authors (IB and JAH) performed a computer-based search of MEDLINE, CINAHL Plus, AMED, GreenFILE, Health Source: Nursing/Academic Edition, PsycARTICLES, Psychology and Behavioral Sciences Collection, PsycINFO, and EMBASE databases (from inception to Nov 2017). The keyword search terms for these specific PA-containing herbs and their alkaloids [“Borago”, “borage”, “pyrrolizidine”, “lycopsamine”, “supinidine”, “amabiline”, “cynaustine”, “Symphytum”, “comfrey”, “symphytine”, “7-acetylycopsamine”, “7-acetylintermediate”, “intermediate”, “lycopsamine”, “symlandine”, “myoscorpine”, “echinatine”, “echimidine”, “heliosupine N-oxide”, “heliotrine”, “lasiocarpine”, “viridiflorine”, “uplandicine”, “Tussilago”,

**Table 1**  
Inclusion and exclusion criteria.

Inclusion criteria	Exclusion criteria
Borago	Other species
Borago	Animal poisoning
Symphytum	Veterinary
Comfrey	Regulation
Tussilago	Food contamination (including honey)
Coltsfoot	Animal experiments
Peer reviewed papers	Mechanisms of toxicity
Human case report	Pharmacokinetics
Human case series	Plant occurrence or prevalence
	Review articles
	Editorials
	Otherwise not relevant

\* Note: only genus and common names were used rather than species, to ensure that cases on related species were captured.

“coltsfoot”, “senkirkine”, “senecionine”] were combined with keyword search terms for PA-related harm [“liver”, “hepat\*”, “megalocytosis”, “venoocclusive disease”, “cirrhosis”, “carcinoma”, “adenoma”, “hyperplasia”, “mutagenicity”, “genotoxicity”, “safety”, “adverse events”, “toxic\*”, “hepatotoxicity”, “drug induced liver injury”, “DILI”, “herb-induced liver injury”, “HILI”, “intrinsic liver toxicity”] using the combination term AND. The search term NOT [“Senecio OR Heliotropium”] was added to reduce the number of irrelevant papers. Bibliographies of case reports discussing the use of PA-containing medicinal plants and potential toxicity, as well as previous reviews, and the authors' personal libraries were hand-searched for additional references. There were no language restrictions.

### 3. Method of data abstraction, inclusion and exclusion criteria

Study selection criteria were defined *a priori* and these are listed in Table 1. Details of the search are described below.

The titles and abstracts of the articles found were screened by two authors IB and JAH, and those that appeared to meet the criteria were examined in further detail. Case reports that discussed the potential toxic effect of the consumption of *Borago officinalis*, *Symphytum officinale* or *Tussilago farfara* in humans were included. Reports were abstracted and assessed by SJE, CA, SS and IB. Any discrepancies were resolved by discussion of the paper or, if necessary, a third reviewer was brought in to arbitrate. Key data abstracted for analysis included the herb reported to be used, its form and dosage, who the prescriber was, duration of treatment, patient details, patients' medical history, use of concomitant medications by the patient, presenting symptom picture, onset and course of symptoms, treatment and care received, investigatory findings, and authors causal attribution.

#### 3.1. Quality assessment of case reports

The quality of each case report was assessed using the Quality of Case Reports of Adverse Events Assessment Instrument (QCRAEI) [31]. Each report was scored out of 40 and ranked into one of five categories from low quality through to high with a sixth category for reports which were unable to be assessed. Details provided in Table 2 describe these categories and those of the other assessment tools used. Papers rated of moderate or good quality were then assessed in terms of causality by both the RUCAM [32] and the WHO-UMC [33]. Authors of published case reports were contacted *via* email or mail in an effort to collect additional data on each case report.

### 4. Results

Searches of MEDLINE, CINAHL Plus, AMED, GreenFILE, Health Source: Nursing/Academic Edition, PsycARTICLES, Psychology and

Behavioral Sciences Collection, and PsycINFO databases yielded a total of 1110 citations. EMBASE discovered 1691 articles. Hand-searching discovered an additional three articles. In total, 2804 reports were screened. Papers were excluded if they were duplicates (720), animal experiments (228), discussions on mechanisms of toxicity or pharmacokinetics (462), review articles and editorials (332), public literature (28), reports on analytic chemistry (85), therapeutic intervention trials (19), reports on other plant species (179), discussed accidental poisonings from PA-containing foods or honey (59), were agricultural or veterinary in nature (106), or were otherwise not relevant (508). Seventy-eight papers were chosen to be examined in greater detail. We excluded 67 of these papers, as they were not original case reports – leaving 11 relevant case reports. A diagram illustrating the flow of citations through the screening process can be seen in Fig. 1.

Eleven case reports and letters published in the peer reviewed literature met the inclusion criteria [34–44]. The search revealed no case reports of adverse events associated with borage. Three reports refer to coltsfoot and eight to comfrey. These cases were published between 1985 and 2013 and reported adverse events considered to be associated with the ingestion of either comfrey or coltsfoot in five countries (three each from the UK and USA, two each from Switzerland and New Zealand and one from Germany). Eight of the cases concerned hepatic veno-occlusive disease (HVOD), two involved pulmonary pathology (one with associated hepatic dysfunction) and one describes a case of deep vein thrombosis and associated pulmonary embolism. The oldest patient affected was 77 years, and the youngest was still *in utero* when adverse impacts were detected. Three of the cases report a fatal adverse event, five patients recovered, two patients became asymptomatic, but were not fully recovered at the time of publication and no information about recovery was provided in one case. Refer to Table 3 which provides key characteristics of the cases by herb, adverse event, outcome, identification, dose and duration and concomitant medicines. Table 5 provides a more detailed case by case summary. None of the case reports include the application of a validated adverse event or liver toxicity criteria such as the Council of International Organizations of Medical Sciences (CIOMS) Suspect Adverse Reactions [45].

#### 4.1. Quality assessment of case reports of adverse events

Based on the QCRAEI, just one of the case reports which concerned comfrey, met the criteria for ‘High’ quality reporting [44]. Four of the reports about comfrey were rated ‘Upper Medium’ quality [34,35,40,43], along with one relating to coltsfoot [36] while two case reports about coltsfoot [39,42] and two about comfrey [37,41] were considered ‘Medium low’ quality. Jones and Taylors [38] short letter about comfrey was excluded from further assessment due its ‘Low’ quality. Given the sparsity of the data reporting on the consumption of the relevant herbs, it was decided only to exclude the reports found to be of low quality from further critical appraisal.

#### 4.2. Application of causality assessments to the case reports and case studies

The WHO-UMC instrument was applied to the ten cases rated of ‘Medium low quality’ and above. The likelihood of the ingested plants having a causative role in the adverse reaction was rated as ‘Probable’ in three cases [35,36,41] and ‘Possible’ in six [34,37,40,42–44], while the case reported by Freshour et al., was found ‘Unassessable’ [39]. The RUCAM was applied to the eight cases of appropriate quality where hepatic involvement was reported. In five of the reports the ingested plant material was rated as ‘Unlikely’ to cause the liver injury [35–37,42,43]. In the cases reported by Miskelly & Goodyear [44] and Rasenack et al. [41], herb-induced liver injury was rated as ‘Possible’. One report by Ridker et al., was found ‘Unassessable’ [34]. The assessment was carried out by four of the authors, independently (IB, SS, SJE and CA). Disagreements were resolved by discussion. Details of the assessments, including the herbs involved, can be viewed in Table 4.

**Table 2**

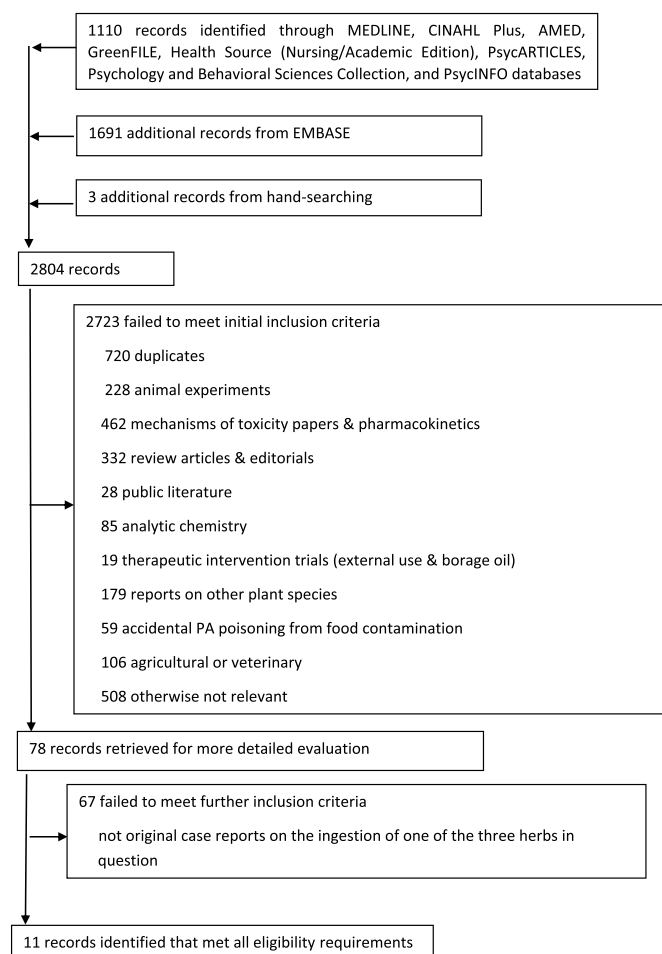
Summary of the assessment instruments role, scoring systems and categories of the assessment instruments, the QCRAEI, the WHO-UMC and the RUCAM.

Instrument	QCRAEI scoring	WHO-UMC methodology	RUCAM scoring
Role to assess:	The quality of reporting of case in which an adverse event occurred.	The association of herb with reported adverse event by a qualitative method.	The association of herb with adverse event employing a quantitative method using an algorithm.
Ranks	High	Certain	Highly probable
1	29–40		≥9
2	Upper medium 22–28	Probable	Probable 6–8
3	Lower medium 15–21	Possible	Possible 3–5
4	Low quality 0–14	Unlikely	Unlikely 1–2
5	Excluded causality ≤ 0	Conditional/Unclassifiable	Unassessable ≤ 0
6		Unassessable/Unclassifiable	

QCRAEI Quality of Case Reports of Adverse Events Instrument Agbabiaka et al., 2008.

WHO-UMC World Health Organization Uppsala Monitoring Centre system for standardised case causality assessment (WHO-UMC).

RUCAM Roussel Uclaf Causality Assessment Method Danan &amp; Teschke 2015.

**Fig. 1.** Flow of citations and articles through the phases of screening and eligibility evaluation.

The causality assessments categorise the probability of association into five ranks in the RUCAM and six in the WHO-UMC system (as shown in Tables 2 and 4). None of the cases met the criteria for the first rank in either rating method; ‘Certain’ (WHO-UMC) or ‘Highly probable’ (RUCAM) or the second category of the RUCAM (‘Probable’). However, eight reports were ranked as ‘Probable/Likely’, the second rank in the WHO-UMC method, or in the third rank of either the RUCAM (‘Possible’) or WHO-UMC (‘Possible’) (See Table 4).

The report by Freshour and colleagues [39] was rated of ‘Medium low’ quality on the QCRAEI and was considered unassessable/unclassifiable by the WHO-UMC method. There was no liver involvement in this case, so it was not rated according to the RUCAM. The report by

Ridker and colleagues [34] was considered ‘unassessable’ when rated on the RUCAM, although the reporting quality was rated ‘upper medium’ and it was assessable by the WHO-UMC method. These findings highlight the pros and cons of using a dual assessment system; results were contradictory in some instances, although more of the human data was assessed for causality in total, than if just one method was relied upon.

There were no published case reports suggesting harm associated with the ingestion of borage. To understand the possible role of *Symphytum officinale* or *Tussilago farfara* in these cases, however, it is necessary to review the source of the herbs and the data authenticating the plant material. If the plants were authenticated in the course of the treatment of the patient, this information was omitted in eight of the 11 case reports (including both the assessable cases involving coltsfoot) and it was incomplete in all of them. Most of the reports omitted a number of other details which explain why only one case [44] was found to be of ‘High’ quality based on the QCRAEI. See Table 4 for details.

Definitive botanical identification is not reported in the nine cases where a causal association is considered a possibility when rated according to RUCAM or the WHO-UMC (see Table 3) [34–37,40–44]. In three cases, evidence of plants containing PAs found in the plant material, or hepatic metabolites from biopsy or autopsy specimens was published [34,36,41]. Additionally, patient case notes provided by the author in the Schroff case provided this information [42].

#### 4.2.1. Case reports referring to Borage (*Borago officinalis*)

No case reports referring to *Borago officinalis* were located in our search.

#### 4.2.2. Case reports referring to Coltsfoot (*Tussilago farfara*)

Both assessable case reports referring to *Tussilago farfara* identified PAs among the plant material ingested. Fatal exposure to unsaturated PA *in utero* is reported by Roulet et al., [36]. An expectorant herbal formula consumed daily by the mother was analysed, along with autopsy specimens. The tea was purchased from a pharmacy and contained ten ingredients, of which 9% w/w was *Tussilago farfara*. The author reports that analysis of the tea by thin-layer chromatography demonstrated a senecionine (and its N oxide) concentration of 0.6 mg/kg dry weight of tea, however daily dosage of the tea was simply reported as a single cup every day for the duration of the pregnancy. Additionally, the reliability of this quantification is in doubt as the stated analytical method was thin-layer chromatography with the full procedure utilised not being described. Without the use of densitometry, thin-layer chromatography does not offer accurate quantification [46].

Senecionine is found in *Adenostyles alliariae* and *A. glabra* [47,48] *Petasites hybridus* [48,50] *Senecio* spp. [49] as well as *Tussilago farfara* [50]. That *Tussilago* was the only, or primary source of senecionine in the expectorant tea has since been questioned. In a letter to the editor

**Table 3**  
Summary case characteristics.

Author date	Coltsfoot			Comfrey							
	Roulet 1988	Schroff 2013	Freshour 2012	Ridker 1985	Weston 1987	Jones 1989	Bach 1989	Yeong 1990	Miskelly 1992	Rasenack 2003	Gyorick 2012
Adverse event/ diagnosis	Hepatic VOD	Hepatic VOD	Deep vein and thrombosis pulmonary embolism	Hepatic VOD	Hepatic VOD	Hepatic VOD	Hepatic VOD	Hepatic VOD	Pulmonary VOD with hepatic involvement	Hepatic VOD	Pulmonary hypertension
Outcome at publication	Death	Partially recovered	Recovered	Recovered	Recovered	Not reported	Partially recovered	Death	Recovered	Death	Recovered
Country	Switzerland	Germany	USA	USA	UK	NZ	USA	NZ	UK	UK	Switzerland
Age/gender	5 days female	63 years female	27 years Male	49 years female	13 years male	NR	47 years female	23 years male	77 years female	Foetus 27 weeks male	66 years female
ID/ID constituents	PAs	NR	NR	PAs	NR	NR	NR	NR	NR	PAs	NR
Dose Duration	Estimated exposure equiv. dry weight herb 0.6 mg/kg b.w./day for 9 months	10 leaves Acute poisoning	NR	Estimated exposure to PAs 0.7-0.74 mg/kg b.w./day for 6 months	No information About 3 years	NR	Up to 10 cups of comfrey tea a day and handfuls of comfrey-pepsin tablets Over 12 months	4-5 young comfrey leaves, steamed daily 7 – 14 days	1/2 tsp three times a day where comfrey 6 parts in 27, 6 days out of 7, for 6 months	2 gm of mixed herbs used daily in cooking during pregnancy Estimated quantity of PAs 0.014 – 0.021 µg/kg b.w./day.	Daily ingestion of 1-1.5L of a herbal tea blend for several months.
Concomitant herbs/medications	Yes	NR	Yes Twelve herbs	Yes	Yes	Yes	NR	No	Yes	Yes Herb teas	Yes, eight other herbs.
Identified/ Not identified	Unidentified		Species named.	Unidentified	Prednisolone Sulphasalazine	Unidentified			Unidentified	Unidentified herbs with no PAs.	Unidentified.
Other	Mother pruritis from 4 <sup>th</sup> month. Caesarean following vaginal bleeding at 36 weeks.				Pre-existing Crohn's disease	Multiple sclerosis	Hospitalised with ascites 6 years after ceasing comfrey.	Oedema noted prior to ingestion of comfrey.		Mother aged 27 years, 3 <sup>rd</sup> pregnancy	History of arterial hypertension, T2DM moderate adiposity and mild renal insufficiency.

VOD Venous-occlusive disease; NR Not reported; PA Pyrrolizidine alkaloids.

published in *Journal of Pediatrics* in 1989 Spang reported that the tea had been further researched by the local cantonal office and was found to have 'contained not only leaves and flowers of *Tussilago farfara* but also roots of *Petasites officinalis* (*Radix petasitidis*)' [51]. These two herbs were also noted in the acute poisoning and development of HVOD in the patient discussed in Schroff et al. [42]. In this case, leaves from these two species were gathered in the wild by a Korean woman living

in Germany who thought she was picking a safe vegetable found in her homeland (Eyer 2018 pers. comm). In the view of the toxicologist, the *Petasites* was much more likely to have been responsible for her acute symptoms than the *Tussilago*.

While it is likely that the adverse events described in these two cases was caused by exposure to unsaturated PAs, the likelihood that the ingested material included a species containing higher concentrations

**Table 4**  
Assessment of case reports reporting an adverse event potentially associated with *Symphytum officinalis* or *Tussilago farfara*, for quality and strength of association.

QCRAEI Quality of reporting	Plant	Author date	WHO-UMC Causality	RUCAM Causality of HILI/DILI
High quality	Comfrey	Miskelly 1992	Possible	Possible
Upper medium quality	Coltsfoot	Roulet 1988	Probably/likely	Unlikely
	Comfrey	Ridker 1985	Possible	Un-assessable
		Weston 1987	Probable	Unlikely
		Yeong 1990	Possible	Unlikely
		Gyorick 2009	Possible	*
Low medium quality	Coltsfoot	Freshour 2012	Un-assessable/ unclassifiable	
		Schroff 2013	Possible	Unlikely
	Comfrey	Bach 1989	Possible	Unlikely
		Rasenack 2003	Probably/Likely	Possible
Low quality	Comfrey	Jones 1989		

QCRAEI Quality of Case Reports of Adverse Events Instrument Agbabiaka et al., 2008.

WHO-UMC World Health Organization Uppsala Monitoring Centre system for standardised case causality assessment WHO-UMC.

RUCAM Roussel Uclaf Causality Assessment Method Danan & Teschke 2015.

\*No liver involvement.

**Table 5**  
Summary of case reports.

Patient	49 year old female [34]
Outcome	Recovered
Location	USA
Source 1	MU-16 (tea from Japan) - exact components not reported
Identification	Tea bag from patient's supply analysed for PAs and pyrrolizidine N-oxide. Repeated 2 years later with specially purchased MU-16.
Dose and duration	480 g of tea over 6 month period, estimated to provide total PA's 0.49–1.45 micrograms/kg of body weight per day.
Source 2	Comfrey-Pepsin capsules (from USA)
Identification	Analysed for PA and pyrrolizidine N-oxide. Note: dry weight equivalent content of comfrey not declared, and powder described as "white"
Does duration	6 capsules/day for 6 months estimated to provide total PA's 14.1 micrograms/kg body weight per day.
Combined dose and duration	Calculated minimum total PA's per day 700–740 micrograms per day over multiple months.
Who prescribed?	Not reported
Prescribed in response to:	Not reported
Concomitant herbs and or medications	Daily vitamin/mineral supplements (A, B C, E, K,Ca, Mg, K, Zn, Fe, lecithin); bovine adrenal extract; 3 cups chamomile tea per week No pharmaceutical medications.
Presenting symptoms, diagnostic details and course of adverse event	Progressive swelling of abdomen & extremities over last 4 months 'Several' hospital admissions without diagnosis. Budd-Chiari syndrome diagnosed on biopsy which revealed centrilobular necrosis and congestion. Hepatic venogram indicated moderate portal hypertension. Side to side portacaval shunt: successfully reduced preportal pressure and ascites; long term follow up after discharge revealed no serious problems except for transient bout of post-shunt encephalopathy attributed to ingestion of > 200 g protein in 12 h period
Medical and or social history	Two adult children.
Authors comment on causation	Hepatic veno occlusive disease due to chronic low dose PA and pyrrolizidine N-oxide ingestion from MU-16 tea and Comfrey-Pepsin capsules.
Patient	13 year old male [35]
Outcome	Recovered from AE in context of pre-existing Crohn's disease
Location	UK
Material ingested	Comfrey tea
Identification	Not reported
Dose and duration	Not reported
Who prescribed?	About 3 years Naturopath
Prescribed in response to:	Management of Crohn's disease following parental decision to discontinue. Pharmaceuticals reintroduced in response to symptom exacerbation.
Concomitant herbs and or medications	Prednisolone and sulphasalazine in acute exacerbations including at time of admission Acupuncture
Presenting symptoms, diagnostic details and course of adverse event	June 1986 presented with fatigue, diarrhoea and weight loss July 1986 hospital admission fatigue, diarrhoea, weight loss, fever, abdominal pain. Examination revealed ascites and tender hepatomegaly Abnormal findings: Hb 117 g/L, bilirubin 26 mmol/L, AST 87 IU/L, albumin 27 g/L, Diagnosis: thrombotic variant hepatic veno-occlusive disease Bx intimal thickening, sinusoidal distension, loss of centrilobular hepatocytes Patient responded well to spironolactone, salt restriction and bed rest. Bowel disease remained relatively inactive with treatment with prednisolone and sulphasalazine, resumed school and 'tolerably well on his medication'
Medical and or social history	Diagnosis of Crohn's disease 1983
Authors comment on causation	Hepatic veno-occlusive disease caused by the ingestion of comfrey tea in child with possibly increased susceptibility due to sub optimal nutritional status secondary to Crohn's disease.
Patient	Neonate female [36]
Outcome	Death
Location	Switzerland
Source	Herbal tea containing <i>Tussilago farfara</i> 9% w/w of tea (9 other unnamed ingredients) <sup>a</sup>
Identification	TLC: 0.6 mg senecionine (measured as N-oxide) per kg dry weight
Dose and duration	A single cup daily through out pregnancy. Level of exposure to patient relatively low (0.60 mg/kg dry weight)
Who prescribed?	Not reported
Prescribed in response to:	Expectorant tea purchased at a pharmacy.
Concomitant herbs and or medications	Tea included 9 other unnamed herbs.
Presenting symptoms, diagnostic details and course of adverse event	Normal pregnancy except pruritis of unknown origin since 4th month. Vaginal bleeding led to caesarean at 36 weeks. Birth weight 2740 g. Within 5 days of birth developed jaundice, hepatomegaly, ascites, apathy. Serum levels of Liver enzymes and bilirubin markedly elevated, level of some coagulation factors below normal. Liver biopsy day 27 of life: centrilobular fibrosis, neovascularisation, iron deposition, widespread circumferential connective tissue occlusion of small and medium hepatic veins. Patient died 38 days after birth. Autopsy confirmed hepatic veno-occlusive disease.
Medical and or social history	Occasional cannabis and hallucinogenic mushrooms months before pregnancy. Two siblings; normal births. Mother no abnormalities.
Authors comment on causation	Prolonged daily exposure to <i>Tussilago farfara</i> - led to cumulative toxicity causing veno-occlusive disease.

(continued on next page)

Table 5 (continued)

Patient	49 year old female [34]
Patient	No details [38]
Outcome	Not reported
Location	NZ
Source	Comfrey tea
Identification	Not reported
Dose and duration	Not reported
Who prescribed?	Self-prescribed
Prescribed in response to:	
Concomitant herbs and or medications	Other herbal teas No pharmaceutical medications
Presenting symptoms, diagnostic details and course of adverse event	Hepatic veno-occlusive disease
Medical and or social history	Multiple sclerosis
Authors comment on causation	Hepatic VOD due to comfrey tea.
Patient	47 year old female [37]
Outcome	Symptoms resolved, but liver damage still evident at time of report.
Location	USA
Source	Comfrey tea and comfrey-pepsin tablets
Identification	No identification reported.
Dose	10 cups of comfrey tea per day plus 'handfuls' of comfrey-pepsin tablets
Duration	Over a year.
Who prescribed?	Recommended by a homoeopathic doctor and purchased in a health food store in 1978
Prescribed in response to:	Vague complaints of abdominal pain, fatigue and allergies.
Concomitant herbs and or medications	None reported.
History and symptoms of Adverse event	1982 LFT revealed aminotransferase levels twice upper limit of normal. Ingestion of comfrey had stopped for 2–3 years. 1986 hepatomegaly and palmar erythema investigated. Serum ALP levels twice normal levels detected. December 1986 hospitalised with 'massive' ascites, hyponatremia and confusion. Patient responded to low sodium diet, but ascites remained. A Denver shunt was inserted in January 1987. Fluid did not re-accumulate. First biopsy: January 1987: diseased histology including perivenular fibrosis consistent with hepatic veno-occlusive disease. 1988 Shunt removed. Second biopsy: September 1989: pathological changes consistent with progressed veno-occlusive disease with further fibrosis and areas of collapse with fibrous septa surrounding parenchyma nodules.
Medical and or social history	No history of alcohol abuse or hepatitis
Authors comment on causation	VOD due to comfrey tea and tablets
Patient	23 year old male [43]
Outcome	Death
Location	New Zealand
Source	Not reported
Identification	Not reported
Dose	4–5 young comfrey leaves, steamed daily
Duration	7–14 days
Who prescribed?	Self-prescribed.
Prescribed in response to:	Not reported.
Concomitant herbs and or medications	No ethanol, marijuana, other medications or radiation exposure.
History and symptoms of Adverse event	When hospitalised patient was emaciated, febrile, with gross ascites, pleural effusions, peripheral oedema and hepatomegaly on percussion. LFT revealed multiple abnormalities. Two biopsies revealed multiple histological abnormalities; severe portal hypertension confirmed by liver angiography. Treatment with diuretics was initiated. Liver function continued to deteriorate. Patient developed a DVT in his left leg attributed to venous stasis secondary to tense ascites and deteriorating renal function. An operation to insert a meso-atrial shunt failed to prevent further deterioration and the patient died 7 days after the operation. Autopsy confirmed veno-occlusive disease.
Medical and or social history	Vegetarian diet for 4 years characterised by 'binge-eating' single foods for days or weeks. Three month history of influenza-like symptoms followed by malaise and night sweats. Peripheral oedema and abdominal distension 3 weeks prior to hospital admission. No other pathology found on autopsy.
Authors comment on causation	Temporal association indicative of causation due to ingestion of comfrey.
Patient	77 year old woman [44]
Outcome	Recovered
Location	UK
Source	Comfrey tea
Identification	Not reported
Dose and duration	1/2 tsp. three times a day where comfrey 6 parts in 27, 6 days out of 7, for 6 months
Who prescribed?	Self-prescribed
Prescribed in response to:	Unclear
Concomitant herbs and or medications	Three herbal formulations; a bowel tonic, a nervine and BFC (Dr Christopher's Bone Flesh Cartilage) which contained 9 species including comfrey and skullcap <sup>b</sup> , which was reported at 1 part in 27

(continued on next page)

Table 5 (continued)

Patient	49 year old female [34]
Presenting symptoms, diagnostic details and course of adverse event	Tiredness, anorexia and weight loss for 6 months, cough with green sputum for 3 months. Dark urine for a few weeks. On examination moderately jaundiced, no pyrexia, hepatosplenomegaly or ascites. Chest clear on auscultation. LFT revealed markedly elevated liver enzymes and bilirubin. Herbs continued. LFT unchanged 1 month later. Chest X-ray found reticulonodular shadowing in the right mid-zone and base. Stopped herbs. LFT repeated in 2 weeks, significant improvement revealed. Symptoms gradually improved over next 6 months. Liver function and chest X-ray were normal after 4 months; and patient began to gain weight.
Medical and or social history	Wasting disease
Authors comment on causation	Close temporal association of ingestion of herbal medicines, particularly the comfrey and skullcap, to changes to liver and lung, absence of other agents and cases reports and animal studies demonstrating veno-occlusive disease caused by PAs.
Patient	Foetus gestational age 27 weeks [41]
Outcome	Death
Location	Germany
Source	Mixture of herbs imported from Turkey used in daily cooking.
Identification	No botanical identification. GC and GC-Mass spectrometry found pyrrolizidine alkaloids consistent with comfrey and heliotropium.
Dose and duration	Estimated the quantity of PAs used in cooking to be 20–30 times the recommended limit of PA or 0.014–0.021 µg/kg b.w./day.
Who prescribed?	Self-prescribed
Prescribed in response to:	Not reported
Concomitant herbs and or medications	Several unidentified herbs in the mixture.
Presenting symptoms, diagnostic details and course of adverse event	27 weeks gestation: Foetal skin oedema and polyhydramnios treated with corticosteroids; 30 weeks gestation: 2000 mL amniocentesis; 31 weeks: Foetal ascites & skin oedema, intraperitoneal calcifications and hepatomegaly. Mother cholestasis with pruritus. Mother treated with cholestyramine; 32 weeks: Mother dyspnoeic; bleeding from placental blood vessel, 2000 mL amniocentesis, and subsequent emergency caesarean; upon birth infant ventilated, multiple blood transfusions. Death in 12 h.
Medical and or social history	In first pregnancy caesarean section was performed postnatal development of the child was normal. 2nd pregnancy: L sided renal atrophy led to nephrectomy and pregnancy spontaneously aborted in 8th week.
Authors comment on causation	VOD seems to be caused by a herbal mixture used for daily cooking which contained pyrrolizidine alkaloids.
Patient	66 year old female [40]
Outcome	Resolved
Location	Switzerland
Source	Mixture of herbs in a tea including Comfrey
Identification	No
Dose	One to one and a half litres a day of a tea containing nine herbs.
Duration	Months
Who prescribed?	Self
Prescribed in response to:	Unclear
Concomitant herbs and or medications	Another 8 unidentified herbs mixed into tea.
Presenting symptoms, diagnostic details and course of adverse event	2006 hospitalised due to progressive dyspnoea. Blood gas analysis showed severe partial respiratory insufficiency. Liver enzymes were mildly elevated. Pulmonary hypertension confirmed. CT scan of chest showed a mild polyserositis with ground glass opacities in both lungs, not characteristic of pulmonary VOD according to two independent experts. At follow up, requested to stop herbal tea. In 2008 admitted with right heart failure. After diuretic therapy, a CT scan of the chest was repeated showing normal lung parenchyma with complete regression of previously reported opacities.
Medical and or social history	History of arterial hypertension, non insulin dependent diabetes, moderate adiposity and mild renal insufficiency.
Authors comment on causation	No other explanation being found, the authors conclude, the pulmonary hypertension to be 'possibly' caused by the prolonged use of herbal remedies containing comfrey.
Patient	27 year old male [39]
Outcome	Recovered
Location	USA
Source	Coltsfoot
Identification	No
Dose	Not reported
Duration	Not reported
Who prescribed?	Self
Prescribed in response to:	No reported.
Concomitant herbs and or medications	Nonsteroidal anti-inflammatories. Twelve other herbs consumed regularly are named.
Presenting symptoms, diagnostic details and course of adverse event	Hospitalised for DVT in right calf and pulmonary embolism. Discontinued herbs. Treated effectively with anti-coagulants which were to be continued on discharge.
Medical and or social history	Right leg pain secondary to back injury 2 weeks prior to admission. Self-treated with bed rest for 14 days. Regular alcohol consumption and 0.5 pack of cigarettes per day.
Authors comment on causation	No direct causal link was identified, but other causes of DVT in a young and otherwise healthy male were excluded, so the authors considered Coltsfoot as a possible causal agent.
Patient	63 year old female [42]
Outcome	Slow recovery

(continued on next page)



Table 5 (continued)

Patient	49 year old female [34]
Location	Germany
Source	Petasites and Tussilago
Identification	(Unclear if the material tested was the material ingested. But some samples of Petasites and Tussilago were examined for PA content found in case notes not publication)
Dose	About 10 leaves, including both of the herbs (about 100 g)
Duration	Consumed in one dose on a single occasion.
Who prescribed?	Self
Prescribed in response to:	Ingredients for a Korean recipe.
Concomitant herbs and or medications	Not reported.
Presenting symptoms, diagnostic details and course of adverse event	Symptom onset 3 h after consumption with nausea and vomiting. Hospitalised next day with abdominal pain and signs of hepatic failure with highly elevated liver enzymes, low prothrombin and thrombocytopenia. Intense treatment for acute poisoning in ICU. Liver biopsy at day 14 revealed veno-occlusive disease. Discharged from ICU at 24 days, still with elevated liver enzymes. Mild ascites and similarly elevated liver enzymes present 3 months later when a liver biopsy showed slight progression of the veno-occlusive liver disease.
Medical and or social history	Recovery complicated by a fall which occurred in hospital and necessitated neurorehabilitation.
Authors comment on causation	'Venocclusive liver-disease caused by pyrrolizidine alkaloid containing herbs may account for significant morbidity.'

<sup>a</sup> Spang (1989) reported that the tea the roots of *Petasites officinalis*, another plant containing unsaturated PA's were found in samples of this tea adds a level of uncertainty to the connection between Tussilago and the death of the infant.

<sup>b</sup> More recent research has found no evidence that Skullcap (*Scutellaria lateriflora*) is hepatotoxic, but that it has frequently been substituted by the hepatotoxic germander (including *Teucrium canadensis* & *T. chamaedrys*). These species are hepatotoxic (Engels 2009).

of PAs substantially weakens the attribution of causation to *Tussilago* [51]. This is certainly borne out by the conclusion reached by the toxicologist who made the assessment that *P. albus* carries a very high risk of toxicity whereas the acute danger of one-off/singular intake of *Tussilago* is very unlikely (Eyer 2018 pers.comm).

#### 4.2.3. Case reports referring to Comfrey (*Symphytum officinale*)

In 2003, Rasenack et al., reported another fatal case, involving exposure to PAs *in utero*, this time referring to comfrey [41]. This report was found to be of 'Low medium' quality and was categorised in the third rank ('Possible') in both the RUCAM and WHO-UMC methods. PAs were found in a combination of herbs used daily in cooking and reportedly contained comfrey. Analysis of specimens taken from a biopsy of the foetal liver revealed dehydrolycopsamine and dehydrointegerrimine, metabolites of lycopsamine and integerrimine, respectively, while the PAs identified in the plant material were lycopsamine and "integerrimine" and their O7-acetyl derivatives. Lycopsamine is found in *Borago officinalis*, *Symphytum officinale*, *S. asperum* and *S. x uplandicum* [48] and rated of mildest PA toxicity [12,]. The reviewers were unable to identify a PA known as "integerrimine". The authors of the case report state the PAs were consistent with heliotropium and comfrey, possibly suggesting echinatin, the only unsaturated PA reported in both plants [52]. However, findings from the foetal biopsy suggests integerrimine may have been present in the cooking herbs. Integerrimine is a macrocyclic diester and thus a member of what is considered to be the most potent class of PAs [12] and is found in *Petasites hybridus*, *Senecio* spp. and *Tussilago farfara*, but not in *Symphytum* spp. [53,50]. Without access to the original toxicology report it is not possible to clear up these discrepancies. However, while exposure to unsaturated PAs is undoubtedly the cause of the tragic death reported, the definitive evidence of a causal role for *Symphytum* or indeed *Tussilago*, is lacking.

Ridker and colleagues report a case of a 49-year-old female with hepatic VOD who ingested a herbal tea (MU-16; manufactured in Japan) and Comfrey-pepsin tablets (manufactured in the USA) [34]. This report was of 'Upper middle' quality on the QCRAEI. Both the tea and tablets were analysed and the patients' exposure to PAs was estimated at 14.6–15.6 µg/kg b.w./day for ~6 months. Assuming a 65 kg bodyweight, this would equate to a daily dose of ~ 975 µg PAs. Given the daily safe recommendation for PAs is generally considered to be 0.1 µg/day [9] (for the most potent PAs), this would equate to a long-term safe dose of 10 µg/d for the PAs contained in comfrey, due to the 100-fold weaker activity of these PAs [12]. This level of ingestion equates to nearly 100 times the recommended safe daily level for

chronic exposure based on relative PA toxicity [54]. However, no specific alkaloid was named, the content of the Comfrey-pepsin capsule was described as a white powder which does not seem consistent with a root extract and the reviewers were unable to access further information. This report was classified as 'Possible' by the WHO-UMC criteria, but 'Unlikely' on the RUCAM. While the characteristic pathology is strongly suggestive of exposure to unsaturated PAs, a direct relationship to comfrey could not be definitively established.

The remaining four cases referring to comfrey include no evidence of plant identification. These cases describe hepatic or pulmonary VOD and include the fatal intoxication of a 23-year-old male after the ingestion of a 4–5 steamed leaves daily for 7 to 14 days [43]. In this case, the patient is described as 'emaciated' with 'gross ascites' when hospitalised and to have eaten a vegetarian diet for 4 years characterised by 'binge-eating' single foods for days or weeks. It is therefore possible that the patient's nutritional status may have been compromised, which may have increased his vulnerability to toxic metabolites of PAs. Unsaturated PAs display no toxicity in their native form and the majority are excreted unchanged in the urine [6]. Biotransformation of the remaining 20% of ingested PAs occurs in the liver and it is this process that results in the formation of toxic metabolites. Three main pathways are involved: N-oxidation to produce pyrrolizidine alkaloid N-oxides (PANOs); hydrolysis to create necines and necic acids; and oxidation to form either pyrrolic esters or dehydropyrrolizidine alkaloids (DHPAs) (5,6,). An important detoxification route for the highly reactive DHPAs occurs *via* the formation of glutathione conjugates; promoting the harmless elimination of these metabolites [6]. *In vitro* models have clearly demonstrated that lowered glutathione status is associated with greater hepatotoxicity from the ingestion of unsaturated PAs due to prolonged exposure and increased concentrations of DHPAs [55–58]. Adequate protein and selenium intake are required for the synthesis of the tripeptide glutathione [59]. The combination of unusual dietary choices and emaciation, reported by Yeong, suggest the patient's glutathione status may have been compromised increasing his susceptibility to PA toxicity.

Clarity around the temporal association of ingestion of the steamed leaves and the onset of the hepatic VOD is also unclear. The patient described by Yeong [43] had a three-month history of influenza-like symptoms followed by malaise and night sweats and both peripheral oedema and abdominal distension three weeks prior to hospital admission while the steamed leaves were apparently eaten for just two weeks prior to hospitalisation (Table 3 and Table 5). This case report was categorised as 'Unlikely' using RUCAM, but 'Possible' when the WHO-UMC method was applied. It is conceivable that the patient was

particularly vulnerable to PAs, however this report does not establish a causal relationship to *Symphytum*.

Weston et al., report the case of a male aged 13 who consumed comfrey tea regularly for about three years as part of a therapeutic regime to manage Crohn's disease [35]. The boy developed hepatic VOD. Withdrawal of the tea was followed by improvement in liver function. This report was classified as 'Probable' on the WHO-UMC scale and 'Possible' on the RUCAM. While the identity of comfrey was not confirmed, the association to PAs is clearly a strong possibility. The patient was previously and at times concurrently, treated with prednisolone for his inflammatory bowel disease. It is possible that concurrent exposure to PA metabolites and a corticosteroid may have increased the toxic potential of the PAs.

Corticosteroids are known to induce hepatic P450 3A activity [59]. A major detoxification route for PAs are initial hydrolysis and N-oxidation to create PANOs. These metabolites can revert back into PAs and then undergo oxidation into DHPAs and pyrrolic esters. This conversion is carried out mostly by cytochrome P-450 (CYP450) monooxygenases, specifically CYP3A and to a lesser degree CYP2B [5,6]. Consumption of agents capable of inducing CYP3A activity concurrently with PAs would be expected to substantially increase the production of highly reactive DHPAs and pyrrolic esters. Therefore, it is possible that the combination of prednisolone with PA containing plants increased the production of the toxic dehydro metabolites and exacerbated the adverse reaction.

The case reported by Miskelly et al., [44], (the only report rated as of 'High' quality by the QCRAEI criteria) involved a 77-year-old female with pulmonary VOD, who used several herbal tea blends for around six months including comfrey. The case was ranked as 'Probable' using the WHO-UMC method and 'Possible' on RUCAM. Withdrawal of the herb tea resulted in improvement of pulmonary symptoms and a drop in liver enzyme values; the patient declined a liver biopsy. Miskelly names both skullcap (presumably *Scutellaria lateriflora*) and comfrey and writes:

*'Both comfrey and skullcap may produce an acute hepatitis' but only comfrey is known to produce pulmonary lesions, and then only in rats. This suggests that the pulmonary lesions were evidence of endothelial hyperplasia and due to comfrey.'* [44]

The hepatotoxicity often attributed to skullcap is now known to be caused by germander (including *Teucrium canadensis* & *T. chamaedrys*) – common adulterants of skullcap. Germander is also known as pink skullcap and has strong morphological similarities with skullcap [60]. The herbal formula taken by this patient may well have included germander, not skullcap. Without identification of the herbs involved, it is not possible to establish the role comfrey (or any other herb) may have played in this case.

The case study reported by Bach et al., [37] is the only study that reports hepatic VOD years after the consumption of the source of the PA had stopped (See Table 5 for more details). The female involved was 47 years old when hospitalised with ascites and diagnosed with hepatic VOD. The authors suggest the pathology was caused by her daily ingestion of '10 cups of comfrey tea' and comfrey-pepsin tablets 'by the handful' for roughly two years. Ridker et al., [34] also report a case in which a patient took comfrey-pepsin tablets. In the case Bach reported, four years after starting the comfrey, a liver function test (LFT) revealed the patient had elevated liver enzymes. By this time the patient had stopped taking comfrey for about two years. Four years after the raised LFT, the patient had developed palmar erythema and hepatomegaly with a liver biopsy the following year confirming hepatic VOD. This patient had no history of hepatitis or alcohol problems. The comfrey tea and tablets were sourced from a health food shop. Previous cases suggest that an analysis of the plant material is the only way to rule out other sources of PAs, however, it is likely that the tablets did contain comfrey. Although the PAs in comfrey are considered to be of the mildest potency, the exposure may have been both prolonged and 'handful' suggests a relatively high dose. When assessed using the WHO-UMC method this case was categorised as 'Possible' and the

further review of the details confirms this assessment. When the RUCAM was applied to the case, the ranking was 'Unlikely' reflecting a lack of detail about concomitant medication and most health history.

## 5. Discussion

An extensive search of the literature revealed 11 case reports where either comfrey or coltsfoot was considered by the authors to have a possible role in the patients' adverse reaction. Reporting in one case was of 'Low' quality (QCRAEI) and another report, which had no hepatic involvement, was found unassessable (WHO-UMC). These cases were not considered reliable enough to inform questions about safety.

Lack of adequate information about the botanical identification of the plants consumed by the patient was a characteristic of the remaining case reports, although three of the reports did refer to PAs found in ingested plants or biopsy material. This limits accurate attribution of causality and the reliable assessment of the safety of comfrey and coltsfoot.

Mistaken identity or substitution may have played a role in three cases and was definitely involved in a fourth. The expectorant tea containing *Tussilago* reported by Roulet et al., [36] may also have contained *Petasites* [51]. It is plausible that germander, rather than skullcap may have been found in the herb blends containing comfrey taken by the patient in the case reported by Miskelly et al., [60]. Rasenack et al., [41], reported on the analysis of plant material and foetal biopsy and autopsy samples in a case where comfrey was suspected. However, some of the PAs named are not found in comfrey, but in *Petasites*, *Senecio* spp. and in *Tussilago* [50]. Personal communication and the full case notes, including the toxicology report make it clear that the patient whose case was reported by Schroff et al., [42] picked and cooked *Tussilago* and *Petasites* mistaking them for a plant native to Korea. These examples emphasise the importance of undertaking and documenting scrupulous identification procedures in relation to herbs potentially associated with an adverse event.

In three of the cases, including one reported by Gyorik et al., [40] where the adverse event involved pulmonary hypertension, patients had a significant health history that may have made them more vulnerable to unsaturated PAs. One case involved a boy with Crohn's disease taking comfrey tea, at times with CYP3A-inducing steroid medications [35]; another woman had several chronic conditions including hypertension and type 2 diabetes mellitus and minor renal insufficiency [40]; while a third patient is reported to have eaten an inadequate diet for an extended period of time and described as emaciated [43]. In these cases, the lack of definitive identification or confirmation of the PAs present means it is challenging to assess causality.

These cases also highlight two of the biologically plausible ways in which PAs may be more or less damaging in different populations and individuals. As discussed in the review by Habs et al., [61], activation of unsaturated PAs via CYP 3A4 enzymes results in the formation of the highly reactive toxic metabolites, however further metabolism can also result in detoxification, with glutathione appearing to be important in this step [61]. Thus, concomitant medications or impaired glutathione status may promote the synthesis, or slow the removal, of the toxic metabolites from the liver. Agents that can induce CYP3A activity include *Hypericum perforatum* and a range of medications such as corticosteroids, aminoglutethimide, bexarotene, bosentan, carbamazepine, dexamethasone, efavirenz, fosphenytoin, griseofulvin, modafinil, nafcillin, nevirapine, oxcarbazepine, phenobarbital, phenytoin, primidone, rifabutin, rifampin, and rifapentine [62]. Co-administration of these agents with medicinal herbs containing unsaturated PAs would thus be expected to increase the risk of adverse events.

In two cases, the patients took comfrey-pepsin tablets, and in both cases the dose may have been relatively high [34,37]. The history of the patient reported by Bach and colleagues [37] follows the pattern of slowly deteriorating liver function eventually diagnosed as HVOD, several years after taking *Symphytum* for an extended period (about two

years). This is the pattern observed in animal studies [2], but not so clearly elucidated in any of the other cases. Both these patients had HVOD which is characteristic of PA poisoning, but lacked confirmatory evidence that the comfrey-pepsin tablets did contain PAs only from *Symphytum* (along with the herbal tea, in the case reported by Ridker et al.) [34].

Two of the cases reviewed involved *in utero* exposure to plants containing PAs, both with fatal consequences [36,41]. Pyrrolizidine alkaloids of higher lipophilicity including pyrrolizidine alkaloid N-oxides (PANOs) are able to pass through the placenta and into breast-milk [6,62]. It is for this reason that the German Federal Ministry of Health has specifically prohibited the use of PA-containing herbal medicines during pregnancy and lactation [54].

There has been a recent upsurge in global research into comfrey which focuses primarily on the proliferative effects and anti-inflammatory activity, which has revealed a possible mechanism of action for its anti-inflammatory effects [22,23]. Further, calls for additional research investigating the root's antimicrobial potential [23,63] have been made. A scoping review found moderate evidence for the external application of comfrey root preparations in musculoskeletal pain and healing abrasions. Although a high risk of bias was noted in some studies, these results corroborate traditional use [64]. Identification of anti-microbial activity and strong antioxidant capacity in some constituents appears to support other traditional applications in the respiratory and gastrointestinal tract, however these cannot be tested in clinical trials due to regulatory restrictions and safety concerns.

It was beyond the scope of this systematic review to investigate or critique *in vitro* or animal studies that have evaluated the potential acute or chronic toxicity and carcinogenicity of unsaturated PAs in general, or the specific PAs found in these three herbs. It should be noted, however, that much of the toxicological research that has resulted in the EMA recommendations was based on animal data using the most potent class of PAs, given in isolation [9]. The EFSA Panel on Contaminants in the Food Chain (CONTAM) conclude their recent statement with recommendations for the collection of toxicological data on the most commonly ingested PAs. The recommendations encourage research which would allow a more accurate and nuanced understanding of the consequences of the consumption of the most commonly ingested PAs. While such research is likely to provide a more reliable basis for the assessment of the risks associated with comfrey, coltsfoot and borage, toxicological studies based on the oral ingestion of phytochemically complex preparations of these herbs may be the most accurate methodology for assessing clinical risk.

## 6. Conclusion

Information gleaned from case studies is often used to inform safety-related decisions and policy. However, there can be flaws in case studies that severely limit the reliability of their conclusions, and these limitations may not be considered by those referencing them. This review has highlighted many of the issues in these published case reports of comfrey and coltsfoot. Our results were similar to case reports detailing potential herbal medicine toxicity in other areas [65] where few case reports were rated as high quality, and poor reporting in regards to dosages and lack of herbal authentication were commonplace.

Case reports in the literature concerning the potential toxicity of oral consumption of *Symphytum officinale* and *Tussilago farfara* in humans have been critically assessed in terms of quality of reporting and for causality. No case reports concerning *Borago officinalis* were located. Without adequate reporting of the botanical identity of the plants involved it is not possible to reliably determine the degree to which these herbs are associated with HVOD or other symptoms or to make definitive statements about the lack of safety of these herbs. The correct authentication of the botanical identity of the plants involved in any adverse event is vital to make meaningful and clinically translatable causality assessments with implications for safe oral consumption of

these PA-containing herbs.

Based on these case reports, the evidence of harm caused by these plants is weak. These cases are up to thirty years old. Insufficient detail and inconsistent information make it difficult for clear assessments of causality; nor is it possible to make such judgements with insufficient information about concomitant medication and without full relevant medical history. While many of the cases were possibly associated with the ingestion of unsaturated PAs, they do not form a reliable body of evidence on which to draw conclusions about the oral consumption of the herbs at the centre of this review. Reference to these reports as additional evidence of the toxicity of PAs or to provide human context in a scientific study, implies a level of toxicity due to these herbs that is yet to be unequivocally established. Retrospective cohort studies might yet provide an estimate of the predictive risk of the ingestion of comfrey, coltsfoot and borage in a clinical context. Further evidence could be provided by toxicological studies based on traditional medicinal use.

## Declaration of Competing Interest

The authors declare no conflict of interest. Funding was provided by the National Institute of Medical Herbalists (United Kingdom), who had no role in the design of the study; in the collection, analyses, or interpretation of data; in the writing of the manuscript, and in the decision to publish the results.

## References

- [1] E. Roeder, Analysis of pyrrolizidine alkaloids, *Curr. Org. Chem.* 3 (6) (1999) 557–576.
- [2] B. Dusemund, et al., Risk assessment of pyrrolizidine alkaloids in food of plant and animal origin, *Food Chem. Toxicol.* 115 (2018) 63–72.
- [3] J.A. Edgar, S.M. Colegate, M. Boppré, R.J. Molyneux, Pyrrolizidine alkaloids in food: A spectrum of potential health consequences, *Food Addit. Contam. Part A Chem. Anal. Control Expo. Risk Assess.* 28 (3) (2011) 308–324.
- [4] O. Mohabbat, An outbreak of hepatic veno-occlusive disease in north-western Afghanistan, *Lancet* 308 (7980) (1976) 269–271.
- [5] P.P. Fu, Q. Xia, G. Lin, M.W. Chou, Pyrrolizidine alkaloids—genotoxicity, metabolism enzymes, metabolic activation, and mechanisms, *Drug Metab. Rev.* 36 (2004) 1–55, <https://doi.org/10.1081/dmr-120028426>.
- [6] R. Moreira, D. Pereira, P. Valentão, P. Andrade, Pyrrolizidine alkaloids: chemistry, pharmacology, toxicology and food safety, *Int. J. Mol. Sci.* 19 (6) (2018), <https://doi.org/10.3390/ijms19061668>.
- [7] J.A. Edgar, R.J. Molyneux, S.M. Colegate, Pyrrolizidine alkaloids: potential role in the etiology of cancers, pulmonary hypertension, congenital anomalies, and liver disease, *Chem. Res. Toxicol.* 28 (1) (2015) 4–20.
- [8] Committee on Herbal Medicinal Products, Public Statement on Contamination of Herbal Medicinal Products/Traditional Herbal Medicinal Products with Pyrrolizidine Alkaloids, European Medicines Agency, London, 2016.
- [9] EFSA CONTAM Panel (EFSA Panel on Contaminants in the Food Chain), H.K. Knutsen, J. Alexander, L. Barregård, M. Bignami, B. Brüschweiler, S. Ceccatelli, B. Cottrill, M. Dinovi, L. Edler, B. Grasl-Kraupp, C. Hogstrand, L.R. Hoogenboom, C.S. Nebbia, I.P. Oswald, A. Petersen, M. Rose, A.-C. Roudot, T. Schwerdtle, C. Vleminckx, G. Vollmer, H. Wallace, J.A. Gomez Ruiz, M. Binaglia, Statement on the risks for human health related to the presence of pyrrolizidine alkaloids in honey, tea, herbal infusions and food supplements, *EFSA J.* 15 (7) (2017) 4908–4934 <https://doi.org/10.2903/j.efsa.2017.4908>.
- [10] L. Chen, P.P.J. Mulder, A. Peijnenburg, I.M.C.M. Rietjens, Risk assessment of intake of pyrrolizidine alkaloids from herbal teas and medicines following realistic exposure scenarios, *Food Chem. Toxicol.* 130 (2019) 142–153.
- [11] L.H. Kruse, T. Stegemann, C. Sievert, D. Ober, Identification of a second site of pyrrolizidine alkaloid biosynthesis in comfrey to boost plant defense in floral stage, *Plant Physiol.* 174 (2017) 47–55.
- [12] K.H. Merz, D. Schrenk, Interim relative potency factors for the toxicological risk assessment of pyrrolizidine alkaloids in food and herbal medicines, *Toxicol. Lett.* 263 (2016) 44–57.
- [13] M.G. Neuman, et al., Hepatotoxicity of pyrrolizidine alkaloids, *J. Pharm. Pharm. Sci.* 18 (4) (2015) 825.
- [14] L. Kristanc, S. Kreft, European medicinal and edible plants associated with subacute and chronic toxicity part I: plants with carcinogenic, teratogenic and endocrine-disrupting effects, *Food Chem. Toxicol.* 92 (2016) 150–164.
- [15] J. Ma, et al., Pyrrole-protein adducts - A biomarker of pyrrolizidine alkaloid-induced hepatotoxicity, *J. Food Drug Anal.* 26 (3) (2018) 965.
- [16] European Medicines Agency, Public Statement on the Use of Herbal Medicinal Products Containing Toxic, Unsaturated Pyrrolizidine Alkaloids (PAs), EMA/HMPC/893108/2011 (2014).
- [17] T.Y. Low, K.O. Wong, A.L.L. Yap, L.H.J. De Haan, I.M.C.M. Rietjens, The regulatory framework across international jurisdictions for risks associated with consumption

- of botanical food supplements, *Compr. Rev. Food Sci. Food Saf.* 16 (5) (2017) 821–834.
- [18] J. Gerard, *The Herbal or General Historie of Plants*, Dover, NY, 1633/1975.
- [19] Scientific Committee of the British Herbal Medicine Association, *British Herbal Pharmacopoeia*, Cowling, British Herbal Medicine Association, 1983.
- [20] R. Weiss, *Herbal Medicine*, Beaconsfield Publishers, UK, 1988.
- [21] C.J. Macalister, A new cell proliferant: its clinical application in the treatment of ulcers, *Br. Med. J.* 1 (2662) (1912), <https://doi.org/10.1136/bmj.1.2662.10.10.300>.
- [22] J. Seigner, M. Junker-Samek, A. Plaza, G. D'Urso, M. Masullo, S. Piacente, et al., A *Symphytum officinale* root extract exerts anti-inflammatory properties by affecting two distinct steps of NF- $\kappa$ B signaling, *Front. Pharmacol.* 10 (2019).
- [23] A. Trifan, et al., Is comfrey root more than toxic pyrrolizidine alkaloids? Salivariolic acids among antioxidant polyphenols in comfrey (*Symphytum officinale* L.) roots, *Food Chem. Toxicol.* 112 (2018) 178–187.
- [24] I. Sowa, R. Paduch, M. Strzemiński, S. Zielińska, E. Rydzik-Strzemska, J. Sawicki, ... M. Wójciak-Kosior, Proliferative and antioxidant activity of *Symphytum officinale* root extract, *Natural Product Research* 32 (5) (2018) 605–609.
- [25] CIOMS, Drug Surveillance: International Cooperation Past, Present and Future. Geneva, Switzerland: Proceedings of the XXVIIth CIOMS Conference 1993, 14–15 September (1993).
- [26] Poisons Standard, Department of Health, 2020, Federal Register of Legislation Australia, Retrieved from, February 2020. <https://www.legislation.gov.au/Details/F2020L00017> 13 Feb 2020.
- [27] M. Whitelegg, The comfrey controversy, in: S. Cant, U. Sharma (Eds.), *Complementary and Alternative Medicines: Knowledge in Practice*, Free Association Books, London, 1996.
- [28] C.A. Gonzalez, J.M. Sanz, G. Marcos, S. Pita, E. Brullet, E. Saigi, et al., Borage consumption as a possible gastric cancer protective factor, *Cancer Epidemiol. Biomark. Prev.* 2 (1993) 157–158.
- [29] S.N. Basar, S. Rani, S.A. Farah, R. Zaman, *Borago officinalis*: a wonder herb, *Int. J. Biol. Pharm. Res.* 4 (2013) 582–587.
- [30] M. Lozano-Baena, I. Tasset, A. Munoz-Serrano, A. Alonso-Moraga, A. de Haro-Ballon, Cancer prevention and health benefits of traditionally consumed *Borago officinalis* plants, *Nutrients* 8 (1) (2016).
- [31] T.B. Agbabiaka, J. Savović, E. Ernst, Methods for causality assessment of adverse drug reactions, *Drug Saf.* 31 (1) (2008) 21–37.
- [32] G. Danan, R. Teschke, RUCAM in drug and herb induced liver injury: The update, *Int. J. Mol. Sci.* 17 (1) (2015).
- [33] WHO-UMC, The Use of the WHO-UMC System for Standardised Case Causality Assessment, [http://www.who.int/medicines/areas/quality\\_safety/safety\\_efficacy/WHOcausality\\_assessment.pdf](http://www.who.int/medicines/areas/quality_safety/safety_efficacy/WHOcausality_assessment.pdf).
- [34] P.M. Ridker, S. Ohkuma, W.V. McDermott, C. Trey, R.J. Huxtable, Hepatic veno-occlusive disease associated with the consumption of pyrrolizidine-containing dietary supplements, *Gastroenterology*. 88 (4) (1985) 1050–1054.
- [35] C.F. Weston, B.T. Cooper, J.D. Davies, D.F. Levine, Veno-occlusive disease of the liver secondary to ingestion of comfrey, *Br. Med. J. (Clin. Res. Ed.)* 295 (6591) (1987) 183.
- [36] M. Roulet, R. Laurini, L. Rivier, A. Calame, Hepatic veno-occlusive disease in newborn infant of a woman drinking herbal tea, *J. Pediatr.* 112 (3) (1988) 433–436.
- [37] N. Bach, S.N. Thung, F. Schaffner, Comfrey herb tea-induced hepatic veno-occlusive disease, *Am. J. Med.* 87 (1) (1989) 97–99.
- [38] J.G. Jones, D.E. Taylor, Hepatic veno-occlusive disease and herbal remedies, *Ann. Rheum. Dis.* 48 (9) (1989) 791.
- [39] J.E. Freshour, B. Odle, S. Rikhye, D.W. Stewart, Coltsfoot as a potential cause of deep vein thrombosis and pulmonary embolism in a patient also consuming kava and blue vervain, *J. Diet. Suppl.* 9 (3) (2012) 149–154.
- [40] S. Gyorik, H. Stricker, Severe pulmonary hypertension possibly due to pyrrolizidine alkaloids in polyphytotherapy, *Swiss Med. Wkly.* 139 (13–14) (2009) 210–211.
- [41] R. Rasenack, C. Muller, M. Kleinschmidt, J. Rasenack, H. Wiedenfeld, Veno-occlusive disease in a fetus caused by pyrrolizidine alkaloids of food origin, *Fetal Diagn. Ther.* 18 (4) (2003) 223–225.
- [42] F. Schroff, N. Felgenhauer, R. Pfab, J. Stenzel, F. Eyer, Acute Liver Failure After Accidental Intake of Pyrrolizidine-Containing Plants, (2013) (264- p).
- [43] M.L. Yeong, B. Swinburn, M. Kennedy, G. Nicholson, Hepatic veno-occlusive disease associated with comfrey ingestion, *J. Gastroenterol. Hepatol.* 5 (2) (1990) 211–214.
- [44] F.G. Miskelly, L.I. Goodyer, Hepatic and pulmonary complications of herbal medicines, *Postgrad. Med. J.* 68 (805) (1992) 935.
- [45] Drug surveillance:international cooperation past, present, future, in: Z. Bankowski, J.F. Dunne (Eds.), *Proceedings of the XXVIIth CIOMS Conference*, Geneva, Switzerland, 1993, p. 107 14–15 September. Figure 1. CIOMS form.
- [46] E. Reich, A. Schibli, *Theoretic Concepts High-Performance Thin-Layer Chromatography for the Analysis of Medicinal Plants*, New York, Thieme, 2007, pp. 61–65.
- [47] R. Chizzola, Pyrrolizidine alkaloids in *adenostyles alliariae* and *a. glabra* from the Austrian alps, *Nat. Prod. Commun.* 10 (7) (2015) 1179–1180.
- [48] E. Roeder, Medicinal plants in Europe containing pyrrolizidine alkaloids, *Pharmazie.* 50 (2) (1995) 83–98.
- [49] J. Robertson, K. Stevens, Pyrrolizidine alkaloids, *Nat. Prod. Rep.* 31 (12) (2014) 1721–1788.
- [50] A. Nedelcheva, N. Kostova, A. Sidjimov, Pyrrolizidine alkaloids in *Tussilago farfara* from Bulgaria, *Biotechnol. Biotechnol. Equip.* 29 (2015) S1–S7.
- [51] R. Spang, Toxicity of tea containing pyrrolizidine alkaloids, *J. Pediatr.* 115 (6) (1989) 1025.
- [52] A. El-Shazly, M. Wink, Diversity of pyrrolizidine alkaloids in the Boraginaceae structures, distribution, and biological properties, *Diversity* 6 (2014) 188–282.
- [53] D. Robins, Pyrrolizidine alkaloids, *Nat. Prod. Rep.* 10 (5) (1993) 487–496.
- [54] Bundesinstitut für Risikobewertung GFHfRA, *Pyrrolizidine Alkaloids in Herbal Teas and Teas*, (2013).
- [55] M. Yang, J. Ruan, P.P. Fu, G. Lin, Cytotoxicity of pyrrolizidine alkaloid in human hepatic parenchymal and sinusoidal endothelial cells: firm evidence for the reactive metabolites mediated pyrrolizidine alkaloid-induced hepatotoxicity, *Chem. Biol. Interact.* 243 (2016) 119–126.
- [56] C.C. Yan, R.J. Huxtable, The relationship between the concentration of the pyrrolizidine alkaloid monocrotaline and the pattern of metabolites released from the isolated liver, *Toxicol. Appl. Pharmacol.* 130 (1) (1995) 1–8.
- [57] Y. Chen, L. Ji, H. Wang, Z. Wang, Intracellular glutathione plays important roles in pyrrolizidine alkaloids-induced growth inhibition on hepatocytes, *Environ. Toxicol. Pharmacol.* 28 (3) (2009) 357–362.
- [58] J. Lamba, Y.S. Lin, E.G. Schuetz, K.E. Thummel, Genetic contribution to variable human CYP3A-mediated metabolism, *Adv. Drug Deliv. Rev.* 54 (10) (2002) 1271–1294.
- [59] P. Matoulkova, P. Pavek, J. Maly, J. Vlcek, Cytochrome P450 enzyme regulation by glucocorticoids and consequences in terms of drug interaction, *Expert Opin. Drug Metab. Toxicol.* 10 (3) (2014) 425–435.
- [60] P. Chen, L.Z. Lin, J.M. Harnly, Mass spectroscopic fingerprinting method for differentiation between *Scutellaria lateriflora* and the germander (*Teucrium canadense* and *T. chamaedrys*) species, *J. AOAC Int.* 93 (4) (2010) 1148–1154.
- [61] M. Habs, K. Binder, S. Krauss, K. Müller, B. Ernst, L. Valentini, M. Koller, A balanced risk-benefit analysis to determine human risks associated with pyrrolizidine alkaloids (PA) – the case of tea and infusions, *Nutrients.* 9 (7) (2017) 717, <https://doi.org/10.3390/nu9070717>.
- [62] Y.T. Liu, H.P. Hao, C.X. Liu, G.J. Wang, H.G. Xie, Drugs as CYP3A probes, inducers, and inhibitors, *Drug Metab. Rev.* 39 (4) (2007) 699–721.
- [63] B. Salehi, F. Sharopov, T. Boyunegmez Tumer, A. Ozleyen, C. Rodríguez-Pérez, S.M. Ezzat, et al., *Symphytum* species: A comprehensive review on chemical composition, food applications and phytopharmacology, *Mol. (Basel, Switzerland)* 24 (12) (2019) 2272.
- [64] R. Frost, H. MacPherson, S. O'Meara, A critical scoping review of external uses of comfrey (*Symphytum* spp.), *Complement. Ther. Med.* 21 (6) (2013) 724–745.
- [65] E. Bostock, et al., Mania associated with herbal medicines, other than Cannabis: A systematic review and quality assessment of case reports, *Front. Psychiatry* 9 (280) (2018).
- [66] W.T. Fernie, *Old-Fashioned Herbal Remedies*, Coles, 1895 (1980).