

Sequential Release and Muscle Slide of Irreparable Rotator Cuff Tears Results in Linear Gains in Tendon Mobility



Michael Riediger, M.D., F.R.C.S.(C.), Jason Vaillancourt, B.Sc., M.P.T.,
Mohammed Shareef, B.M.Sc., M.Sc.Mgmt.,
Allan Young, M.B.B.S., M.Sp.Med., Ph.D., F.R.A.C.S. (Orth.), and
Benjamin Cass, M.B.B.S., M.S., F.R.A.C.S. (Orth.)

Purpose: The purposes of this study were to examine the technique of the supraspinatus and infraspinatus muscle slide for the treatment of rotator cuff tears and to quantify the amount of release and resultant tendon excursion at their insertion sites in cadavers. **Methods:** Twelve shoulders in 6 human cadavers were dissected. Their average age at time of death was 84 years. Though a large open posterior incision, artificial rotator cuff tears were created, if not already present. Standard arthroscopic release was completed. Muscle slide technique was then performed for the supraspinatus and infraspinatus muscles in quartiles, with tendon excursion measured at each interval. **Results:** The average muscle length from its most medial border to the tendinous insertion was 130 mm and 145.8 mm for the supraspinatus and infraspinatus, respectively. Progressive release of the muscle origin from lateral to medial in 25% increments corresponded to a 6.47-mm lateral shift of the tendon to a maximum of 25.8 mm before complete release of the supraspinatus muscle was achieved. For the infraspinatus, it was an average of 5.38 mm at each 25% interval to a maximum of 21.5 mm. The only restraint to mobility were the motor branches attached to the undersurface of each muscle belly. **Conclusions:** An additional 25.8 mm (supraspinatus) and 21.5 mm (infraspinatus) of tendon excursion was produced when 100% of the muscle was released from its underlying fossa. At that juncture, tendon excursion was limited by tension placed on each muscle's respective neurovascular supply. Furthermore, sequential release of each muscle resulted in a predictable and consistent gain in tendon mobility, with an average of 6.47 mm and 5.38 mm for each quartile of muscle release in the supraspinatus and infraspinatus from lateral to medial. **Clinical Relevance:** Tension at the repair site is a contributing factor to poor outcomes after arthroscopic rotator cuff repair of massive rotator cuff tears. This study quantifies the tendon mobility that may be gained following additional muscle slide techniques, and the addition of this technique may contribute to a tension-free repair.

From the Department of Orthopaedic Surgery Northern Ontario School of Medicine, Thunder Bay, Ontario, Canada (M.R., J.V.); Department of Surgical and Anatomical Science Facility, University of Technology Sydney, Ultimo New South Wales, Australia (M.S.); and Sydney Shoulder Research Institute, St Leonards, New South Wales, Australia (A.Y., B.C.).

The authors report no conflicts of interest in the authorship and publication of this article. Full ICMJE author disclosure forms are available for this article online, as [supplementary material](#).

Received July 25, 2022; accepted June 2, 2023.

Address correspondence to Michael Riediger, M.D., F.R.C.S.(C.), Big Thunder Orthopaedics Associates, 984 Oliver Road, Suite 206, Thunder Bay, ON, P7B 7C7, Canada. E-mail: Michael.riediger@medportal.ca

© 2023 THE AUTHORS. Published by Elsevier Inc. on behalf of the Arthroscopy Association of North America. This is an open access article under the CC BY-NC-ND license (<http://creativecommons.org/licenses/by-nc-nd/4.0/>).
2666-061X/22839

<https://doi.org/10.1016/j.asmr.2023.100756>

Good clinical outcomes have been observed in small to medium-sized rotator cuff tears;¹⁻⁴ however, repair of large- to massive-sized tears have a higher failure rate.⁵⁻⁷ They may involve multiple tendons, and the quality of remaining muscle can be poor. Additionally, tendon retraction and associated tension across the repair site are thought to be reasons for higher failure rates after repair of large to massive rotator cuff tears.⁸ As a result, various surgical techniques have been developed to decrease tension over the repair site, while maintaining the anatomic footprint of the tendon.

In 1965, Debeyre et al.⁹ introduced the original description for a supraspinatus muscle slide and

advancement technique for massive rotator cuff tears. They described a large transacromial approach and a muscle slide of the supraspinatus followed by rotator cuff repair. Of 23 patients, 56% had a satisfactory result, which was described as 140° of pain-free abduction range of motion. The ability of the transposed muscle to contract was also confirmed by electromyography. This original technique, described by Debeyre et al.,⁹ was reappraised in 1980 by Ha'Eri et al.¹⁰ Thirty-seven patients with rotator cuff tears were treated with the same muscle advancement technique. Patients were evaluated on a 100-point outcome scale based on their pain, active range of motion, abduction strength, and ability to return to work. A score greater than 62 was considered a satisfactory outcome. On this basis, 22 patients (60%) were considered to have had a satisfactory outcome. These authors concluded the muscle slide and advancement technique described by Debeyre et al.⁹ may be valuable for the repair of large and chronic tears of the supraspinatus muscle.

Furthermore, in 2019, Yokoya et al.¹¹ sought to incorporate a minimally invasive form of the muscle advancement in combination with a standard arthroscopic repair. In a modification of the original technique, they treated 47 patients with rotator cuff tears in a retrospective cohort study. In a control group, 21 patients were treated with standard arthroscopic rotator cuff repair. The remaining 26 patients were treated with arthroscopic rotator cuff repair with muscle advancement through a separate mini-open incision. There was no significant difference in clinical outcomes between the two groups. However, the failure and retear rates were significantly lower in the study group than in the control group (23.1% and 52.4%; $P = .03$). A lower retear rate represents an

opportunity to improve long-term anatomic and clinical outcomes. Therefore, the purposes of this study were to examine the technique of the supraspinatus and infraspinatus muscle slide for the treatment of rotator cuff tears and to quantify the amount of release and resultant tendon excursion at their insertion sites in cadavers. The hypothesis was that a muscle slide would provide a tendon excursion that was proportional to the amount of muscle released.

Methods

Surgical Technique

Twelve shoulders in 6 human cadavers were dissected. There were 6 right shoulders and 6 left shoulders. There were 2 males and 4 females. The average age at the time of death was 84 years (range: 69-102 years).

All cadavers were fresh frozen. Each cadaver was taken through a range of motion prior to dissection, allowing at least 90° of abduction. All dissections were performed with the cadaver in the prone position and table reverse Trendelenburg to 45° to allow simultaneous access to both shoulders. This sequence was performed to allow complete access to the supraspinatus and infraspinatus for measurements of the muscles, as well as their neurovascular structures.

A large L-shaped incision was made extending from the superomedial border of the scapula across the lateral border of the acromion and back down to the inferior pole of the scapula (Fig 1). An osteotomy of the acromial arch and dissection through the acromioclavicular joint allowed the deltoid to be reflected off the shoulder providing complete visualization of the rotator cuff insertion on the humeral head. At this time, the

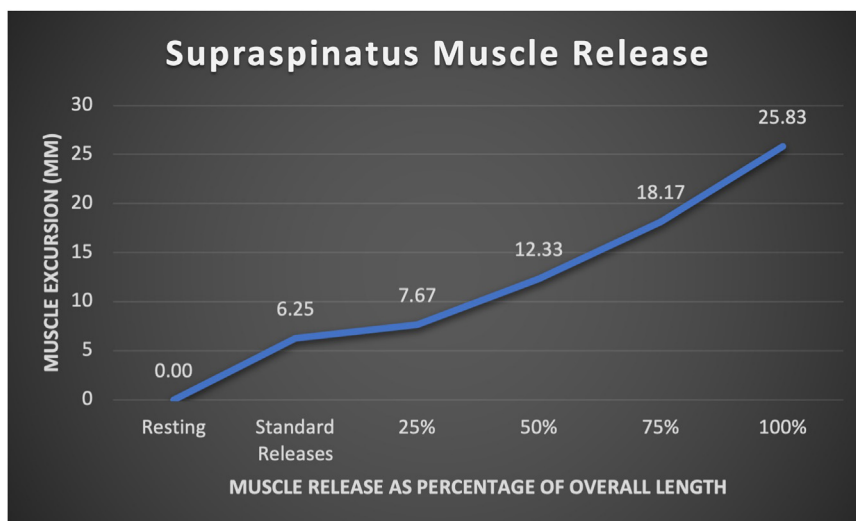
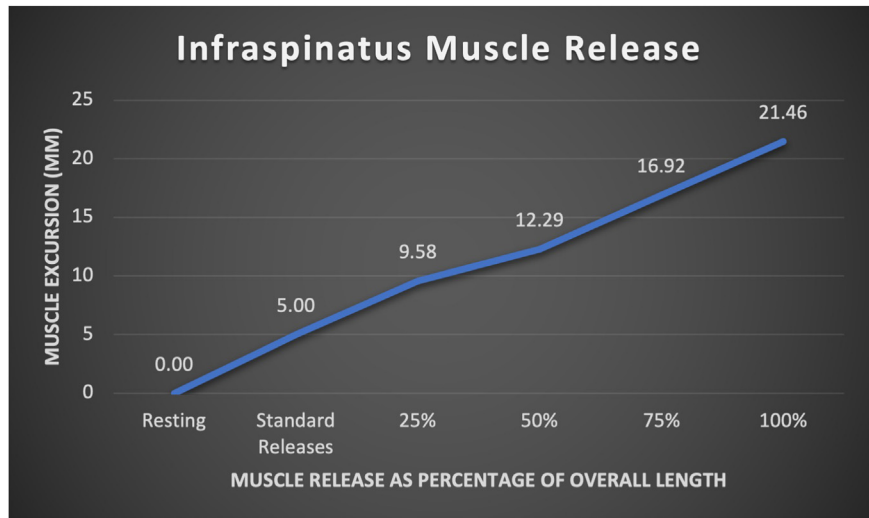


Fig 1. Supraspinatus muscle lateral excursion in mm as a percentage of muscle release.

Fig 2. Infraspinatus muscle lateral excursion in mm as a percentage of muscle origin release.



following measures were collected: length of the supraspinatus muscle and tendon, presence of a previous rotator cuff tear, length of the infraspinatus muscle and tendon, and location of insertion on the humeral head.

Next, an artificial tear was created in the supraspinatus muscle insertion if one was not already present. Following the operative technique of Yokoya et al.,¹¹ a standard arthroscopic release was performed, including synovectomy, suprascapular nerve release, and a subacromial decompression. The cuff was tensioned laterally, and our first measurement of lateral displacement was made prior to the muscle slide. We then turned our attention to performing the muscle slide described by Debeyre et al.⁹ Knowing the total length of the muscle from medial border to glenoid rim allowed for a simple calculation of muscle length that could then be divided into quarters. These quartiles were marked on the Bristow elevator. The muscle was then elevated from lateral to medial one quarter at a time, and at each point, the tendon was laterally tensioned to create displacement, which could then be measured. This process was continued until the muscle was completely released from the supraspinatus fossa. The same procedure was then carried out on the infraspinatus muscle simulating a massive two-tendon tear. The fascia of each muscle was carefully elevated out of the osseous fossa subperiosteally to maintain a fascial plane between the elevator and the motor branches of the suprascapular nerve. At each measurement point, tension on the suprascapular nerve was visually observed at the suprascapular notch. As well as the spinoglenoid notch. Once the muscle had been fully elevated from the infraspinatus fossa, the muscle could be reflected, and the motor branches could be counted, as well as inspected for any damage created by the subperiosteal elevation.

Results

The average length of the supraspinatus muscle was 130 mm (SD 17 mm), and the tendon was 22.5 mm (SD 5.4 mm). The average muscle length of the infraspinatus was 145.8 mm (SD 13.8 mm), and the tendon was 21.7 mm (SD 2.5 mm). In one of the shoulders, there was a pre-existing full-thickness supraspinatus tear present measuring 0.5 cm in the medial-lateral plane and 1 cm anteroposterior.

Performing the standard intra-articular releases and a suprascapular nerve release provided an average of 6.25 mm (SD 6.8 mm) of tendon mobility for the supraspinatus. Progressive subperiosteal muscle belly release of the supraspinatus muscle achieved an average mobility of the musculotendinous unit of 7.7 mm at 25% (SD 8.3 mm), 12.33 mm (SD 8.9 mm) at 50%, 18.1 mm (SD 7.8 mm) at 75% and 25.8 mm (SD 5.6 mm) at 100% (Fig 1). Once the supraspinatus had been completely released from the floor of the fossa complete lateral excursion of the tendon was possible.

Release of the infraspinatus revealed less tendon excursion with sequential release. This was due, in part, to the method of release from the superomedial corner of the infraspinatus fossa. A large portion of the fascial origin remained intact at the inferior pole of the scapular border. Arthroscopic release provided 6.7 mm (SD 5.77 mm) of tendon mobility. Following lateral to medial release, 9.6 mm (SD 8.6 mm) of mobility was achieved at 25%, 12.3 mm (SD 9.6 mm) at 50%, 16.9 mm (SD 9.0 mm) at 75%, and 21.5 mm (SD 11.7 mm) at 100% of the muscle release (Fig 2).

Discussion

In this study, a supraspinatus and infraspinatus rotator cuff muscles were sequentially released, and muscle slide was performed to measure the amount of release

and the resultant tendon excursion available. Large and massive rotator cuff tears often have tendon retraction, which, after repair, is associated with tension at the repair site leading to poorer outcomes. The muscle slide technique has been used as an option to achieve a tension-free repair of the tendon insertion on the greater tuberosity of the humerus in chronic retracted rotator cuff tears. The most important finding of this study was once the supraspinatus had been completely released from its fossa, the tendon had gained an average of 25.8 mm of excursion and was limited only by tension placed on their neurovascular structures. This finding was also reported by Warner et al.¹² in a similar article studying the relationship of the neurovascular structures following mobilization. They also reported a maximum gain of 25 mm before tension began on the first motor branch of the suprascapular nerve to the supraspinatus.

The first stage of this study was a standard intra-articular release. This yielded 6.25 mm of tendon excursion. It is well known in orthopaedic surgery that more tendon retraction preoperatively is a risk factor for poor postoperative outcomes, specifically retear. Shin et al.¹³ studied differences between a retear and intact group. They reported preoperative tendon retraction of 20.4 mm in the retear group and 11.7 mm in the intact group. Our study demonstrated the limited tendon excursion gained from standard intra-articular release.

Following the standard intra-articular releases, the muscle was released from lateral to medial in 25% increments until complete release from the fossa was achieved. We observed that sequential release allowed for tendon mobility in a predictable and linear fashion. For every 25% of muscle release, the tendon achieved an average of 6.47 mm of additional excursion for the supraspinatus and 5.38 mm for the infraspinatus. As the overall muscle length was relatively consistent between shoulders, we found that releasing a percentage of the muscle relative to its overall length could be done in a reproducible method by measuring the approximate length of the muscle externally and sliding the key elevator subperiosteally to a predetermined depth to release the origin of the muscle belly.

The muscle slide technique has been used to good effect, including low postoperative retear rates and good functional outcomes,^{14,15} despite complete release of the supraspinatus and infraspinatus muscle belly from their fossa. Gupta et al.¹⁶ describes the muscle slide technique in detail and explains that the superficial fascia, as well as other fascial attachments to the rhomboids and deltoid are left intact. It is assumed that the muscle scars back to their scapular fossae. In our study, we identified that partial and sequential release yields a predictable and linear amount of tendon mobility gain. Future research may be warranted to

further explore functional outcomes of a muscle slide technique with only partial muscle subperiosteal elevation and release.

Limitations

This study is not without limitations. First, a large open dissection was required over the shoulder for measurement and data collection purposes. This inherently caused a release of the muscular fascia from the overlying skin and adipose tissue, which may have likely contributed to a greater tendon mobility. Additionally, while performing the muscle slide, tension on the neurovascular structures was visually observed and not quantified. This may have resulted in inexact measurements. However, it is likely that this error is small. This approach also reflects a surgeon's approach to the muscle slide where intraoperative tension measurement is uncommon. Finally, the use of cadaver specimens did not allow for an accurate baseline measurement of tissue elasticity when performing standard releases prior to the muscle slide.

Conclusions

In this study, an additional 25.8 mm (supraspinatus) and 21.5 mm (infraspinatus) of tendon excursion was produced when 100% of the muscle was released from its underlying fossa. At that juncture, tendon excursion was limited by tension placed on each muscle's respective neurovascular supply. Furthermore, sequential release of each muscle resulted in a predictable and consistent gain in tendon mobility, with an average of 6.47 mm and 5.38 mm for each quartile of muscle release in the supraspinatus and infraspinatus from lateral to medial.

References

1. Peters KS, McCallum S, Briggs L, Murrell GAC. A comparison of outcomes after arthroscopic repair of partial versus small or medium-sized full-thickness rotator cuff tears. *J of Bone Joint Surg Am* 2012;94:1078-1085.
2. Bell S, Lim YJ, Coghlan J. Long-term longitudinal follow-up of mini-open rotator cuff repair. *J Bone Joint Surg Am* 2013;95:151-157.
3. Van der Zwaal P, Thomassen BJW, Nieuwenhuijse MJ, Lindenburg R, Swen JWA, Van Arkel ERA. Clinical outcome in all-arthroscopic versus mini-open rotator cuff repair in small to medium-sized tears: A randomized controlled trial in 100 patients with 1-year follow-up. *Arthroscopy* 2013;29:266-273.
4. Neyton L, Godenèche A, Nové-Josserand L, Carrillon Y, Cléchet J, Hardy MB. Arthroscopic suture-bridge repair for small to medium size supraspinatus tear: Healing rate and retear pattern. *Arthroscopy* 2013;29:10-17.
5. Sugaya H, Maeda K, Matsuki K, Moriishi J. Repair integrity and functional outcome after arthroscopic double-row rotator cuff repair. *J Bone Joint Surg Am* 2007;89:953-960.

6. Galatz LM, Ball CM, Teefey SA, Middleton WD, Yamaguchi K. The outcome and repair integrity of completely arthroscopically repaired large and massive rotator cuff tears. *J Bone Joint Surg Am* 2004;86:219-224.
7. Henry P, Wasserstein D, Park S, et al. Arthroscopic repair for chronic massive rotator cuff tears: A systematic review. *Arthroscopy* 2015;31:2472-2480.
8. Davidson PA, Rivenburgh DW. Rotator cuff repair tension as a determinant of functional outcome. *J Shoulder Elbow Surg* 2000;9:502-506.
9. Debeyre J, Patte D, Elmelik E. Repair of ruptures of the rotator cuff of the shoulder. *J Bone Joint Surg Br* 1965;47:36-42.
10. Ha'eri GB, Wiley AM. Advancement of the supraspinatus muscle in the repair of ruptures of the rotator cuff. *J Bone Joint Surg Am* 1981;63:232-238.
11. Yokoya S, Nakamura Y, Harada Y, Ochi M, Adachi N. Outcomes of arthroscopic rotator cuff repair with muscle advancement for massive rotator cuff tears. *J Shoulder Surg* 2019;28:445-452.
12. Warner JP, Krushell RJ, Masquelet A, Gerber C. Anatomy and relationships of the suprascapular nerve. *J Bone Joint Surg* 1992;74:36-45.
13. Shin YN, Ryu KN, Park JS, Jin W, Park SY, Yoon YC. Predictive factors of retears in patients with repaired rotator cuff tears on shoulder MRI. *AJR Am J Roentgenol* 2018;210(1):134-141.
14. Morihara T, Kida Y, Furukawa R, et al. Therapeutic outcomes of muscular advancement by an arthroscopic-assisted modified Debeyre-Patte procedure for irreparable large and massive rotator cuff tears. *J Orthop Sci* 2018;23:495-503.
15. Yokoya S, Nakamura Y, Harada Y, Ochi M, Adachi N. Outcomes of arthroscopic rotator cuff repair with muscle advancement for massive rotator cuff tears. *J Shoulder Elbow Surg* 2019;28:445-452.
16. Gupta A, Ker AM, Maharaj JC, Veen EJD, Cutbush K. All-arthroscopic muscle slide advancement technique to repair massive retracted posterosuperior rotator cuff tears. *Arthrosc Tech* 2021;10:1439-1446.